

## PLACENTAL SITE TROPHOBLASTIC TUMOR – A SYSTEMATIC REVIEW

Arumugam Velappan<sup>1</sup>, Deepa Shunmugam<sup>2</sup>, Biju Azariah M<sup>3</sup>

<sup>1</sup>Associate Professor, Department of Medical Oncology, Tirunelveli Medical College, Tamilnadu, India.

<sup>2</sup>Associate Professor, Department of Surgical Oncology, Tirunelveli Medical College, Tamilnadu India.

<sup>3</sup>Senior Resident, Department of Medical Oncology, Tamilnadu, India.

Received : 07/05/2023  
Received in revised form : 03/06/2023  
Accepted : 15/06/2023

**Keywords:**

Placental site trophoblastic tumor,  
Gestational trophoblastic neoplasia,  
Pathology, Diagnosis.

Corresponding Author:

**Dr. Deepa Shunmugam,**  
Email: oncodeepa@gmail.com

DOI: 10.47009/jamp.2023.5.3.428

Source of Support: Nil,  
Conflict of Interest: None declared

*Int J Acad Med Pharm*  
2023; 5 (3); 2178-2182



### Abstract

**Background:** Placental site trophoblastic tumor (PSTT) is a rare form of gestational trophoblastic disease (GTD) with both benign and malignant potential. PSTT arises from invasive intermediate trophoblasts and is characterized by the absence of chorionic villi. This tumor exhibits a wide clinical spectrum, ranging from benign to aggressive behavior, making early diagnosis and management challenging. Pathologically, PSTT shows pleomorphic intermediate trophoblast cells infiltrating between smooth muscle cells, along with necrosis, hemorrhage, and fibrinoid deposition. Immunohistochemistry analyses reveal positive expression of markers such as prolactin, cytokeratin, melanoma adhesion molecule, cyclin E, and CD146. Clinical presentation includes abnormal vaginal bleeding or amenorrhea, and metastasis can occur in various organs. Diagnosis relies on laboratory tests, including measurement of serum human chorionic gonadotrophin (hCG) and human placental lactogen (HPL), as well as pathological evaluation. Imaging techniques like ultrasound and MRI are valuable for assessing tumor extent and metastasis. Treatment involves surgical removal of the tumor, often by hysterectomy, and chemotherapy may be used in advanced or metastatic cases. Prognosis varies, with a recurrence rate of approximately 30% and higher mortality in advanced stages. New treatment strategies, including targeted therapy and immunological checkpoints, are being explored. Developing effective treatment strategies for PSTT is crucial due to its challenging clinical behavior.

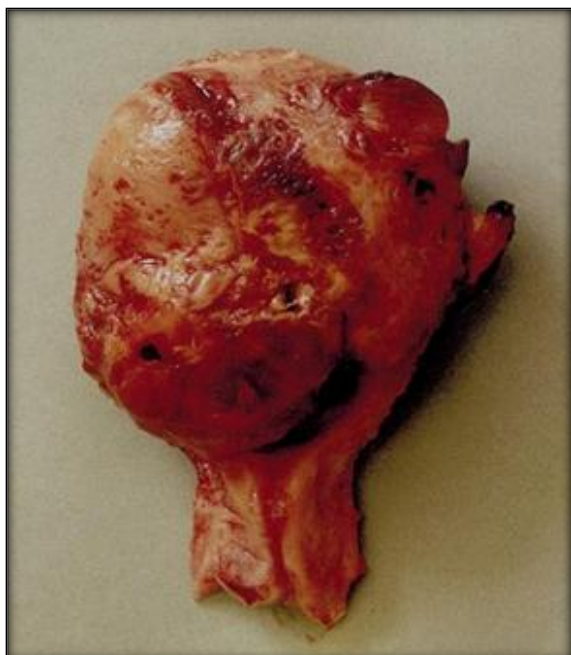## INTRODUCTION

Placental site trophoblastic tumor (PSTT), is a rare form of gestational trophoblastic disease (GTD) contributing to 1-2% of all gestational trophoblastic neoplasia (GTN). They arise from invasive intermediate gestational trophoblasts which are responsible for subsequent embryo implantation.<sup>[1]</sup> Previously, PSTT was thought to be benign in nature and hence was termed ‘trophoblastic pseudo tumor by Kurman and Scully in 1976.<sup>[2]</sup> But with more understanding of the malignant behavior of the tumor, the nomenclature was changed to PSST in 1981 by Scully and Young, to account for both the benign and malignant potentials of this tumor which has since then been adopted by the World Health Organization (WHO).<sup>[3]</sup> In the spectrum of GTN, partial or complete hydatidiform mole is considered to be benign, while choriocarcinoma (CC) and PSTT are considered as malignant.<sup>[4]</sup> The etiology and risk factors for the development of PSTT are not clearly understood. World wide data shows that that

the disease-specific mortality of PSTT is higher than other GTD subtypes (16.1% for PSTT, 6.5% for hydatidiform moles, and 13.4% for choriocarcinoma).<sup>[5]</sup> The rarity and wide clinical spectrum of this disease ranging from benign to aggressive behavior with fatal outcome, provides challenges in making correct early diagnosis and deciding the management.<sup>[5,6]</sup>

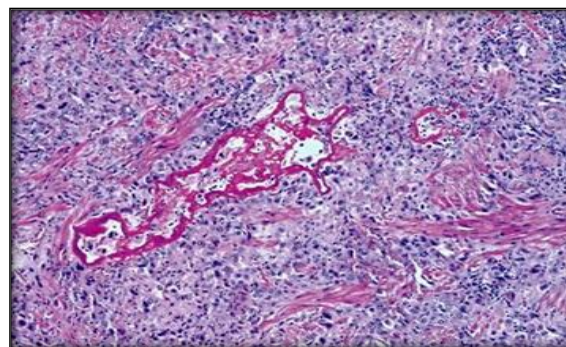
### Pathology

PSTT originates from the proliferation of the intermediate interstitial trophoblast, at the placenta implantation site and is characterized by absence of chorionic villi. On gross examination, PSTT is usually a polypoidal lesion, and protrudes into uterine cavity or infiltrates the uterus. Occasionally it can transit the deep myometrium and extend to the serosa (Figure1).<sup>[7]</sup> Cut section usually shows grey or yellow tumor with a circumscribed border and variable areas of hemorrhage or necrosis.



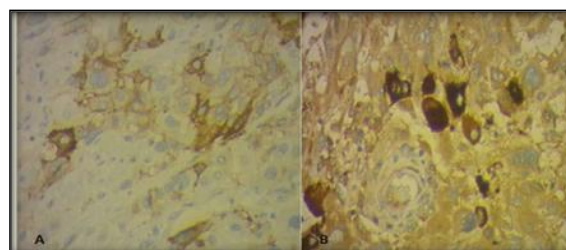
**Figure 1: Hysterectomy specimen showing Placental site trophoblastic tumor, an ill- defined mass which has replaced and permeated myometrium**

On histopathological examination, the tumors are characterized by gross nuclear and cytoplasmic pleomorphism of intermediate trophoblast cells. The proliferation of the intermediate trophoblastic cells evolves like nodule, which then infiltrates and proliferates between the smooth muscle cells separating them as cords and sheets (Figure 2) (Picture courtesy of Rebecca N Baergen MD). There is angioinvasion of the decidual spiral arterioles, associated with necrosis and hemorrhage. They also present monomorphic population of large polyhedral cells with irregular hyperchromatic nuclei. Nuclear atypia is usually amphophilic but can also be eosinophilic or clear. Spindling of tumor cells can be present. The occasional observation of fibrinoid deposition, if present is a typical feature of this tumour. In PSTT, neoplastic trophoblastic cells have abundant amphophilic, occasional eosinophilic or clear cytoplasm, variable nuclear size, and shape with marked hyperchromasia, nuclear grooves and pseudoinclusions. Nucleoli are generally prominent and mitotic count is usually between 2 and 4 per 10 high-power fields.<sup>[8]</sup> The endometrium adjacent to the neoplastic cells may show a pseudo decidual change.



**Figure 2: PSTT showing bright pink fibrinoid deposition and proliferation of extra villous trophoblasts showing variable atypia and splitting apart muscle fibers. (H&E, magnification 10x.)**

In PSTT, the nuclei are at different stages of mitosis and hence the mitotic figure may vary. And so, the biologic behaviour of PSTT cannot be predicted from the microscopic features alone.<sup>[6,9]</sup> Genotypically, PSTTs are usually diploid and have a female predominance or 46XX.<sup>[10]</sup> Immunohistochemistry analyses show the expression of prolactin (HPL), cytokeratin (CK), melanoma adhesion molecule (Mel-CAM), Cyclin E and CD146 diffusely positive in the cytoplasm of PSTT tumor cells, while the expression of HCG is locally positive (Figure 3 B) and Vimentin is negative.<sup>[11,12,13]</sup> Epithelial membrane antigen (EMA) and placental alkaline phosphatase (PLAP) are focally positive (Figure 3 A).<sup>[14]</sup> 50-100% of intermediate trophoblasts show positivity for human placental lactogen (HPL) and fewer than 10% of tumor cells stain for human chorionic gonadotrophin (hCG). This can be used in diagnosis and in discriminating PSTT from carcinoma or sarcomas. Expression of Ki67, a nuclear antigen, correlates to the proliferation potential of the tumor tissue. In PSTT, Ki67- positive cells could reach 15%, while in choriocarcinoma it may surge to 60–70%.<sup>[15]</sup> Due to the absence of the syncytiotrophoblast cells, PSTT expresses a lower level of serum beta-HCG than choriocarcinoma. Choriocarcinoma can be differentiated from PSTT by these two points. Ki67- positive cells exceeding 50% and elevated serum beta-hCG level, favors the diagnosis of choriocarcinoma. Table 1 shows the summary of the expression patterns of different markers in three types of gestational trophoblastic neoplasia (GTN) tissues.<sup>[15]</sup>



**Figure 3: Immunohistochemical testing showing focal positivity for placental alkaline phosphatase (A) and hCG (B) (×100)**

**Table 1: Summary of the expression patterns of different markers in three types of Gestational Trophoblastic Neoplasia (GTN) tissues**

|          | PSST | ETT | CC  |
|----------|------|-----|-----|
| CK       | +++  | +++ | +++ |
| HPL      | +++  | -/+ | +/- |
| HCG      | -/+  | -/+ | +++ |
| CD146    | +++  | -/+ | -/+ |
| Ki67     | +    | +   | +++ |
| EMA      | ++   | +++ | NA  |
| P63      | -    | +++ | -/+ |
| Vimentin | -    | +   | -   |

-, 0-5%; +, 5-30%; ++, 31-60%; +++, >60 % expression  
 ETT- epithelial trophoblastic tumour, NA- not available; PSST- placental sitetrophoblastic tumour.CC Choriocarcinoma

### Clinical Presentation

PSTT mostly affects the women of reproductive age group. PSTT can develop after any type of pregnancy. PSTTs most commonly develop after a term gestation, but also occur after a molar pregnancy in approximately 8 percent of cases. The risk factors for the development of PSST is not clearly defined, however menarche after age of 12 years, poor bleeding during menstrual period and oral contraceptive use have been linked inconsistently with PSTT.<sup>[16]</sup> The most common presenting symptoms are abnormal vaginal bleeding or amenorrhea. Due to nonspecific signs and symptoms, the clinical diagnosis of PSTT can be difficult. At presentation, 70% patients have disease localized to the uterus, while 30% of patients has metastatic disease. The metastases sites are lungs, liver, vagina, lymph nodes, brain, bladder, ovary or other organs.<sup>[17,18]</sup> Metastasis may also occur years after the initial diagnosis of PSTT.

Rarely, PSTT manifests with preeclampsia, beta-HCG triggered hyperthyroidism, unspecific symptoms, such as nausea or hemoptysis, galactorrhea, polycythemia and even cutaneous metastases. Nephrotic syndrome or haematuria related to glomerular membrane deposition of immunoglobulin and fibrin may occur in 10% of patients. It resolves after removal of the tumour. Virilization due to raised testosterone levels, secondary to an ovarian response to gonadotrophin drive from the tumor, is also reported. PSTT is staged according to the FIGO staging of gestational trophoblastic disease.

### Investigations and Diagnosis

#### LABORATORY AND PATHOLOGICAL DIAGNOSIS

In most patients with PSTT, serum levels of  $\beta$ -hCG are not highly elevated, which differs from other forms of gestational trophoblastic disease. Serum values of hCG in patients with choriocarcinoma, tends to be in the range of 103-107 IU/litre, whereas even with bulky PSTT, the levels are in the range of only 102-103 IU/liter.<sup>[6,17]</sup> Hence, the levels of hCG are not an accurate indication of tumor burden and cannot be used as a reliable tumor marker. Measurement of Human placental lactogen (HPL), a late trophoblastic product, may be useful in

identification and monitoring of PSTT.<sup>[19,20]</sup> Pathological evaluation is also necessary for a definite diagnosis. Initial curettage is often equivocal and the diagnosis can be missed if fragments showing muscle invasion by intermediate trophoblasts are not seen. The endometrial tissue evaluation of HPL is useful in diagnosis of initial stage of PSTT after a hysteroscopic biopsy or D&C. Failure to respond or persistence of raised HCG levels in a GTN case treated with methotrexate can raise the suspicion of a PSTT. The Ki-67 index, which is a surrogate marker for mitotic activity, shows 10-20% positivity in PSTT and is useful for differentiating this lesion from exaggerated placental site reaction where the Ki-67 index is less than 1% and choriocarcinoma, which shows >50% positivity. A more recent marker for differentiating between choriocarcinoma and PSTT is the association of free non-hyperglycosylated b-hCG with PSTT, while in choriocarcinoma hyperglycosylated hCG is present and there is no free b- hCG.

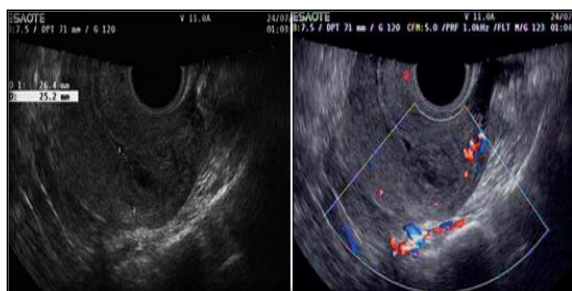### Imaging Features

Imaging plays an important role in assessing the local extent of disease and systemic surveillance. Ultrasound (USS) examination, including Doppler imaging, is helpful in the diagnosis of gestational trophoblastic disease but is not specific.<sup>[6,14,17]</sup> USS examination shows a solid mass within the endometrial cavity or in the myometrium with or without the classical echogenic foci and vascular enlargement containing clusters of little cysts. Color Doppler finding of markedly increased uterine vascularity characterized by low diastolic flow suggesting tumor angiogenesis is highly characteristic of PSTT ( Figure 4 A, B).<sup>[21]</sup>

On MR imaging, the distortion of the junctional zone caused by a myometrial or endometrial mass, which is typically isointense to normal myometrium on T1-weighted images and isointense to slightly hyperintense to the myometrium on T2-weighted images is observed with disruption of the junctional zonal anatomy.<sup>[14]</sup>

The most common site of metastasis is the lungs, therefore imaging of the lungs is usually recommended. Chest CT is more sensitive in detection of lung metastases with greater accuracy.

For staging assessment, total body CT and contrast dye may be substituted by 18-fluorodeoxyglucose positron emission tomography CT-scan. MRI imaging of the brain and CT of the abdomen are recommended to those with lung metastases, which may alter staging and subsequent management.



**Figure 4: Transvaginal ultrasound images in a Type I PSTT: (a) demonstrating a heterogeneous echogenic mass located in the uterine cavity and (b) showing minimal blood flow at the border of the lesion on color Doppler imaging**

### Treatment and Prognosis

Since the biological behavior of PSTT is highly variable which does not fit into well-defined prognostic groups, the standard treatment is surgery. The principle is to remove tumor and/or tumor involving organs, by total hysterectomy with or without bilateral salpingo-oophorectomy with lymphatic sampling. Simple hysterectomy is the preferred treatment for most patients. Stage I patients can achieve complete remission with surgery alone. Adjuvant chemotherapy does not seem to offer any significant benefit.

Conducting a lymphadenectomy at stage 1 seems particularly appropriate only in case of risk factors such as a myometrium invasion superior to 50%.<sup>[15]</sup> In premenopausal women, the standard practice is to preserve the ovaries unless there is evidence of ovarian disease. It has been reported in recent years that reproductive function (uterus) could be persevered after successful removal of PSTT. The level of  $\beta$ -hCG drops significantly in about a month after surgical treatment.<sup>[22]</sup> With locally advanced or metastatic disease, tumor reductive surgery should be performed if disease is considered resectable, and they require combination chemotherapy.<sup>[23]</sup> PSTT is characterized by a 61% resistance or incomplete response to chemotherapy agents.<sup>[20]</sup> Metastatic low-risk tumors (FIGO Stages II and III,) should be treated with 5-day dosage schedules of methotrexate and actinomycin D, with cure rates approaching 100%. High-risk patients will need adjuvant chemotherapy, a multi-agent platinum-based regimen lasting for 8 weeks of normal HCG levels, such as the most common EMA/CO, EMA/ EP or the combination TE/TP.<sup>[24,25,26,27]</sup> For second-line therapies, there is no consensus, the EMA/EP scheme is proposed in the case of recurrences after EMA/CO, or BEP or VIP schemes. The resection of residual lumps after chemotherapy is recommended.

The clinical and biological behavior of PSTT is difficult to predict and no definitive prognostic index or scheme exists. The FIGO staging and WHO prognostic system for GTN are currently being used but do not correlate very well in PSTT.<sup>[27]</sup> Other poor prognostic factors are advanced stage (FIGO stage III or IV), higher mitotic index, coagulative tumor necrosis, presence of cells with clear cytoplasm a vascular invasion; a deep myometrium invasion; an invasion of the serous membrane and persistence of high post-operative beta-HCG levels and, more generally, a maximum HCG level > 1000mIU/ML. A high mitotic index, is described as more than 5mitosis per 10 high-power fields. Risk of death is reported 14 times greater if mitotic figures were greater than 5/10 HPF. High mitotic index is associated with not only metastatic disease but appears to be an indicator of recurrence too. When a PSTT is malignant, it is fairly resistant to chemotherapy.<sup>[28,29]</sup>

The PSTT has a good prognosis when diagnosed at the first stage. Although most patients with PSTT can be cured, a recurrence rate of approximately 30% has been reported. In case of recurrence, the following outcome for patients with PSTT is worse than other forms of GTD which have long-term remission up to 75% to 90% with second-line treatment.<sup>[29]</sup>

Developing new strategy for treatment of PSTT is of great significance. Recently, certain treatment strategies, such as targeted therapy for vascular growth factors and immunological checkpoints have drawn attention.<sup>[30]</sup> Targeted therapy can increase the efficacy while reducing side effects because they selectively target specific pathways. Standard chemotherapy affects most proliferating cells, while target-based treatment is designed to inactivate molecular pathways, such as PI3K and MAPK signaling pathways that are essential for tumor-cell growth and survival. Studies have found increased expression of vascular endothelial growth factor (VEGF) and TGF $\beta$ 3 in PSTT tissues.<sup>[31,32]</sup> It is reported that there were differences in the expression of EG-VEGF and PKR1/PKR2 between normal villous tissues and choriocarcinoma cell lines, and that PKR1 was mainly expressed in cytotrophoblasts, while PKR2 was mainly expressed in extravillous trophoblasts and syncytiotrophoblasts.<sup>[33]</sup>

### CONCLUSION

PSTT is a type of gestational trophoblastic neoplasm with very low incidence and benign characteristics. The presenting symptom of placental-site trophoblastic tumor is usually atypical, and serum  $\beta$ -hCG levels are usually only modestly elevated or normal in placental-site trophoblastic tumor. Accurate diagnosis depends on histopathology with special immune histochemical staining. Among the imaging techniques, trans vaginal Doppler



ultrasound examination plays a key role to localize and hypothesize the malignant nature of the lesion. MRI is superior to ultrasound in evaluating tumor location and extension of extrauterine pelvic tumor. Chest CT is much more sensitive and allows detection of lung metastases with greater accuracy. Surgery is the most appropriate treatment option in most cases of placental-site trophoblastic tumor, since it is less chemosensitive than invasive mole or choriocarcinoma.<sup>[33]</sup> Most PSTT patients are young women hence fertility preservation is an important consideration. Chemotherapy resistance is a main obstacle for PSTT patient prognosis, but the underlying mechanism is still unclear. More studies are needed to explore the exact mechanism of PSTT, so as to develop novel treatment strategies, and finally improve prognosis for PSTT patients.

## REFERENCES

- Cole ME, Broaddus R, Thaker P, et al. Placental-site Trophoblastic Tumors: A Case of Resistant Pulmonary Metastasis. *Nat Clin Pract Oncol* 2008;5(3):171-5.
- Kurman RJ, Scully RE, Norris HJ. Trophoblastic pseudotumour of the uterus: an exaggerated form of "syncytial endometritis" simulating a malignant tumour. *Cancer*. 1976; 38:1214-19.
- Scully RE, Young RH. Trophoblastic pseudotumour: a reappraisal. *Am J Surg Pathol*.1981; 5:75-6.
- Lurain JR. Gestational trophoblastic disease II: classification and management of gestational trophoblastic neoplasia. *Am J Obstet Gynecol*.2011;204:11-8.
- Huang F, Zheng W, Liang Q, Yin T. Diagnosis and treatment of placental site trophoblastic tumor. *Int J Clin Exp Pathol*. 2013;6(7):1448-51.
- Ajithkumar TV, Abraham EK, Rejnish kumar R, et al. Placental site trophoblastic tumor. *Obstet Gynecol Surv* 2003;58:484-8.
- Gillespie AM, Liyim D, Goepel JR, Coleman RE, Hancock BW. Placental site trophoblastic tumour: a rare but potentially curable cancer. *Br J Cancer*. 2000;82(6):1186-90.
- Placental site trophoblastic tumor (PSTT): a case report and review of the literature Claudia Zampacorta , Maria Paola Pasciuto , Benedetta Ferro , Alessandro Lucidi et al. *Pathologica* 2023 Apr;115(2):111-116.
- Kurman RJ. The morphology, biology and pathology of intermediate trophoblast: A look back into the present. *Hum Pathol* 1991;22:847-55.
- Zhao S, Sebire NJ, Kaur B, et al. Molecular genotyping of placental site and epithelioid trophoblastic tumours; female predominance. *Gynecol Oncol* 2016;3:501-7.
- Luiza JW, Taylor SE, Gao FF, Edwards RP. Placental site trophoblastic tumor: immunohistochemistry algorithm key to diagnosis and review of literature. *Gynecol Oncol Case Rep*. 2014 ;7:13-5.
- Kar A, Mishra C, Biswal P, Kar T, Panda S, Naik S. Differential expression of cyclin E, p63, and Ki-67 in gestational trophoblastic disease and its role in diagnosis and management: A prospective case-control study. *Indian J Pathol Microbiol*.2019; 62:54-60.
- McCarthyWA, Paquette C, Gundogan F, LawrenceWD. Comparison of p63 and p40 immunohistochemical stains to distinguish epithelioid trophoblastic tumor from other trophoblastic lesions. *Int J Gynecol Pathol*. 2018 ;37:401-4.
- Guido Martin Rey Valzacchi Placental site trophoblastic disease . *Int J Gynecol Cancer* 2019;0:1-6.
- Feng X, Wei Z, Zhang S, Du Y, Zhao H. A Review on the Pathogenesis and Clinical Management of Placental Site Trophoblastic Tumors. *Front Oncol*. 2019;9:937.
- De Nola R, Schönauer LM, Fiore MG, Loverro M, Carriero C, Di Naro E. Management of placental site trophoblastic tumor: Two case reports. *Medicine (Baltimore)*. 2018;97(48):e13439.
- Bouquet de la Jolinière J, Khomsy F, Fadhlou A, Ben Ali N, Dubuisson JB, Feki A. Placental site trophoblastic tumor: a case report and review of the literature. *Front Surg* 2014;1:31.
- Zhang HY, Yue XN, Tao X, Xi ML, Yan AQ, Lu X. Placental site trophoblastic tumor presented with vaginal metastasis. *Int J Clin Exp Med*. 2015;8(2):2993-97.
- Lucas R, Cunha TM, Santos FB. Placental site trophoblastic tumor: a case report and review of the literature. *J Radiol Case Rep*. 2015;9(4):14-22.
- Kim SJ. Placental site trophoblastic tumour, *Best Pract Res Clin Obstet Gynaecol*. 2003;17(6):969-84.
- Y. Zhou, H. Lu, C. Yu, Q. Tian. Sonographic characteristics of placental site trophoblastic Tumor Ultrasound. *Obstet Gynecol* 2013; 41: 679-684.
- Placental site trophoblastic tumour: the rarest subtype of gestational trophoblastic disease
- Mariana M Chaves , Tiago Maia , Teresa Margarida Cunha , Vera Furtado Veiga . *BMJ Case Rep* 2020 Oct 10;13(10).
- Schmid P, Nagai Y, Agarwal R et al. Prognostic markers and long-term outcome of placental-site trophoblastic tumours: a retrospective observational study. *Lancet*. 2009; 374:48-55.
- Deng L, Zhang J,Wu T, Lawrie TA. Combination chemotherapy for primary treatment of high-risk gestational trophoblastic tumour. *Cochrane Database Syst Rev* 2013;(1):CD005196.
- Escobar PF, Lurain JR, Singh DK, et al. Treatment of high-risk gestational trophoblastic neoplasia with etoposide, methotrexate, actinomycin D, cyclophosphamide, and vincristine chemotherapy. *Gynecol Oncol*. 2003;91(3):552-57.
- Seckl MJ, Sebire NJ, Fisher RA, et al. ESMO Guidelines Working Group Gestational trophoblastic disease: ESMO Clinical Practice Guidelines for diagnosis, treatment and follow-up. *Ann Oncol*. 2013;24 (6):39-50.
- A Review of Current Management of Placental Site Trophoblastic Tumor and Epithelioid Trophoblastic Tumor Wesley C Burkett , John T Soper . *Obstet Gynecol Surv* 2022 Feb;77(2):101-110.
- Schmid P, Nagai Y, Agarwal R, et al. Prognostic markers and long-term outcome of placental-site trophoblastic tumours: A retrospective observational study. *Lancet* 2009;374:48-55.
- Horowitz NS, Goldstein DP, Berkowitz RS. Placental site trophoblastic tumors and epithelioid trophoblastic tumors: biology, natural history, and treatment modalities. *Gynecol Oncol* 2017; 144:208-14.
- Brown J, Naumann RW, SecklMJ, Schink J. 15years of progress in gestational trophoblastic disease: scoring, standardization, and salvage. *Gynecol Oncol*.2017;144:200-7.
- Bolat F, Haberal N, Tunali N, Aslan E, Bal N, Tuncer I. Expression of vascular endothelial growth factor (VEGF), hypoxia inducible factor 1 alpha (HIF-1alpha), and transforming growth factors beta1 (TGFbeta1) and beta3 (TGFbeta3) in gestational trophoblastic disease. *Pathol Res Pract*.2010; 206:19-23.
- SinghM, KindelbergerD, Nagymanyoki Z,Ng SW,Quick CM, Yamamoto H, et al. Vascular endothelial growth factors and their receptors and regulators in gestational trophoblastic diseases and normal placenta. *J Reprod Med*.2012; 57:197-203.
- Hoffmann P, Saudi Y, Benharouga M, Graham CH, Schaal JP, Mazouni C, et al. Role of EG-VEGF in human placentation: physiological and pathological implications. *J Cell Mol Med*.2009; 13:2224-35.
- Placental site trophoblastic tumor: Successful treatment of 13 cases. Amy L. Alexandera , Anna E. Strohla, Kruti P. Maniarb , John R. Luraina. *Gynecol Oncol Rep* 2020 Feb 13;32:100548.